


# Evaluation of the Therapeutic Effects of Docosahexaenoic Acid on Aspirin-Induced Gastric Ulcer Healing and Oxidative Stress Markers in Rats

Hassan Valadbeigi<sup>1</sup> , Mohammad Hossein Haddadi<sup>1</sup>  

<sup>1</sup> Clinical Microbiology Research Center, Ilam University of Medical Sciences, Ilam, Iran

Article Info	ABSTRACT
<b>Article type:</b> Original article	<b>Introduction:</b> Nonsteroidal anti-inflammatory drugs (NSAIDs), such as aspirin, are widely used but often induce gastric ulcers as a major side effect. This study aimed to investigate the protective and healing effects of docosahexaenoic acid (DHA), an omega-3 fatty acid, against aspirin-induced gastric ulcers in rats.
<b>Article History:</b> Received: July. 11, 2025 Revised: Aug. 15, 2025 Accepted: Sep. 02, 2025 Published Online: Sept. 22, 2025	<b>Materials &amp; Methods:</b> Male Wistar rats were divided into four groups: an ulcer control group, two DHA-treated groups (low dose and high dose), and a group receiving omeprazole as a standard anti-ulcer agent. Ulcers were induced by oral administration of aspirin for three consecutive days, followed by 14 days of treatment.
 <b>Correspondence to:</b> Mohammad Hossein Haddadi Clinical Microbiology Research Center, Ilam University of Medical Sciences, Ilam, Iran	<b>Results:</b> Macroscopic and histopathological evaluations revealed significant improvements in ulcer healing in DHA-treated groups, especially at the higher dose, with reduced inflammatory cell infiltration, restored mucosal integrity, and normalized glandular architecture. Biochemical analyses demonstrated dose-dependent increases in antioxidant enzymes SOD and CAT, along with significant reductions in oxidative (MDA) and inflammatory (MPO, TNF- $\alpha$ , IL-1 $\beta$ , and IL-6) markers. DHA-H showed comparable or greater efficacy than omeprazole in reducing oxidative stress and IL-1 $\beta$ levels, though omeprazole remained more effective in ulcer area reduction.
<b>Email:</b> haddadi841@gmail.com	<b>Conclusion:</b> DHA, particularly at higher doses, ameliorates aspirin-induced gastric injury by modulating oxidative stress and inflammatory pathways. These findings suggest the potential of DHA as a complementary or alternative therapy to PPIs in managing NSAID-induced gastropathy, especially for patients unresponsive to or intolerant of standard treatments. While our study demonstrates the therapeutic potential DHA, the lack of signaling pathway analysis, such as NF- $\kappa$ B/NLRP3, limits mechanistic depth. Future studies should address this gap to validate molecular targets.
	<b>Keywords:</b> Omega 3, Docosahexaenoic Acid, Aspirin, Gastric ulcer, Healing, Oxidative stress

## ➤ How to cite this paper

Valadbeigi H, Haddadi MH. Evaluation of the Therapeutic Effects of Docosahexaenoic Acid on Aspirin-Induced Gastric Ulcer Healing and Oxidative Stress Markers in Rats. *Journal of Health Sciences Perspective*. 2025; 1(4):01-13.

## Introduction

Gastric ulcers represent a significant global health concern affecting approximately 10% of the population worldwide. Non-steroidal anti-inflammatory drugs (NSAIDs), particularly aspirin, are among the most common causes of gastric ulcers due to their widespread use for pain management, inflammation control, and prevention of cardiovascular events. Aspirin-induced gastric ulcers occur when the drug disrupts the protective mucosal barrier of the stomach, leading to tissue damage and ulceration. This damage is characterized by mucosal erosion, inflammation, and oxidative stress (1).

Aspirin and other NSAIDs have been widely used to establish animal models of gastric ulcers due to their reliable ulcerogenic properties (2). The primary mechanism by which aspirin induces gastric ulcers involves the inhibition of prostaglandin synthesis (3). Prostaglandins, particularly prostaglandin E<sub>2</sub> (PGE<sub>2</sub>), play a crucial protective role in maintaining gastric mucosal integrity by increasing mucus secretion, maintaining blood flow, and decreasing acid secretion (2). Beyond the disruption of prostaglandin pathways, aspirin-induced gastric ulcers are associated with increased oxidative stress markers such as malondialdehyde (MDA) and elevated proinflammatory cytokines including tumor necrosis factor- $\alpha$  (TNF- $\alpha$ ), interleukin-6 (IL-6), and interleukin-10 (IL-10). Concurrently, there is a reduction in gastroprotective antioxidant enzymes such as superoxide dismutase (SOD), glutathione (GSH), and catalase (CAT) (2).

Docosahexaenoic acid (DHA), a long-chain omega-3 polyunsaturated fatty acid primarily found in fish oil, has garnered scientific interest for its potential therapeutic effects on various inflammatory conditions. Recent research has explored the role of DHA in gastric ulcer healing, particularly those induced by aspirin. DHA possesses anti-inflammatory, antioxidant, and tissue-regenerative properties that may counteract the damaging effects of aspirin on gastric mucosa. The evaluation of

therapeutic effects of DHA on aspirin-induced gastric ulcers involves examining histological changes in gastric tissue, monitoring ulcer healing rates, and measuring oxidative stress markers to determine its protective mechanisms (4, 5).

Research has increasingly focused on DHA, a long-chain omega-3 polyunsaturated fatty acid, for its protective effects against gastric damage caused by non-steroidal anti-inflammatory drugs, including aspirin (6). Fish oil, which is rich in omega-3 fatty acids including DHA, has been shown to reduce gastric acid secretion, providing a key mechanism for its gastroprotective effects (7). The cytoprotective action of DHA against gastric mucosal damage works through multiple pathways. First, it may increase the levels of catalase enzyme within the peroxisomes and cytoplasm, enhancing defense against free oxygen radicals. Second, supplemented DHA can replace polyunsaturated fatty acid components of cell membranes that have been damaged by reactive oxygen species (6, 7).

Beyond its gastroprotective effects, DHA has demonstrated regenerative properties in other tissues, suggesting similar benefits for gastric tissue healing. Research has shown that DHA treatment improves nerve regeneration, enhances sensitivity, and accelerates wound healing in diabetic mouse models (8, 9).

The main objectives of this study were to evaluate the anti-ulcerative, antioxidant, and anti-inflammatory effects of DHA in an aspirin-induced gastric ulcer model in rats.

## Materials and methods

### Reagents

DHA was purchased from Sigma Aldrich (CN=D2534, USA). Enzyme-linked immunosorbent assay (ELISA) kits were purchased from Bioassay Technology Laboratory (CN=S-20052, China). Aspirin was purchased from Osveh pharmacology. Co (Iran).

## **Experimental Animals**

In this study, male Wistar rats (180–220 g) were randomly assigned into four experimental groups (n=6 per group) following induction of gastric ulcers using aspirin. Gastric ulcers were induced by administering aspirin orally at a dose of 250 mg/kg once daily for three consecutive days. The doses of DHA (100 mg/kg and 300 mg/kg) were selected based on previous studies that demonstrated the efficacy and safety of these doses in rodent models of gastric injury and oxidative stress (5, 10). After ulcer induction, the rats were treated daily for 14 days with one of the following interventions: Group I served as the ulcer control and received no therapeutic agent post-ulcer induction; Group II received DHA at a low dose of 100 mg/kg/day; Group III received a high dose of DHA at 300 mg/kg/day; and Group IV, serving as a positive control, received omeprazole at 20 mg/kg/day. All treatments were administered orally, and rats were housed under standard laboratory conditions with ad libitum access to food and water. Body weights were recorded at baseline, mid-treatment, and prior to sacrifice to assess treatment tolerability. Post-ulcer induction, rats were treated daily for 14 days with the assigned interventions. At the end of the treatment period, euthanasia was performed via cervical dislocation under continued anesthesia (ketamine/xylazine, 100/10) to minimize distress, and their stomachs were harvested for macroscopic ulcer evaluation, histopathological examination, and biochemical assays of oxidative stress markers. This protocol allowed for a systematic assessment of the ulcer healing potential and antioxidant effects of DHA compared to a standard anti-ulcer drug.

## **Induction of gastric ulcer**

Induction of gastric ulcers was achieved using a standardized aspirin-induced ulceration protocol. Prior to ulcer induction, all rats were fasted for 24 hours with free access to water to ensure an empty stomach and consistent baseline gastric conditions across groups. The rats were then administered

aspirin orally via gavage at a dose of 250 mg/kg body weight once daily for three consecutive days. This dosage and duration were selected based on pilot study and confirmation of gastric ulcer induction.

## **Macroscopic and histopathological evaluation**

At the end of the treatment period (14 days post-ulcer induction), rats were euthanized under anesthesia, and the stomachs were excised, opened along the greater curvature, rinsed with cold saline, and examined for both macroscopic and microscopic parameters.

Macroscopic evaluation involved quantifying the ulcer index, calculated based on the number and severity of visible gastric lesions using a standardized scoring system. Each ulcer was measured, and the ulcer area was computed in mm<sup>2</sup>, with a cumulative ulcer index determined per rat. Representative sections of gastric tissue were fixed in 10% formalin, embedded in paraffin, and sectioned at 5 µm thickness using a microtome. Sections were stained with hematoxylin and eosin (H&E) and examined under a Nikon Eclipse E200 microscope (Nikon Corporation, Japan). These sections were examined under a microscope to assess epithelial integrity, mucosal edema, inflammatory cell infiltration, hemorrhage, and regenerative changes, with each histological feature graded using a semi-quantitative scoring system (0 = None, 0.5 = Minimal, 1 = Mild, 2 = Moderate, 3 = Severe).

We performed a histopathological examination on gastric biopsies. The ulcer evaluation was done on the whole stomach on day 14 to assess the healing effect. Ulcer indexing was performed according to the previous study by Bhattacharya et al. (2006). To measure the ulcer area, the length and thickness of the ulcer in mm<sup>2</sup> were measured at a magnification of 40× and the information was processed using ImageJ software. The area of the gastric ulcer in each section (5 sections/sample) was determined. Gastric histology was evaluated by A pathologist who was blinded to the other assays and results.

## Oxidative stress biomarkers in gastric tissue

To assess oxidative stress status, gastric tissue homogenates were prepared and analyzed for key biochemical markers. Lipid peroxidation was measured via MDA levels using the thiobarbituric acid reactive substances (TBARS) assay. Antioxidant enzyme activities, including SOD and CAT, were quantified using spectrophotometric assays based on their ability to scavenge free radicals or decompose hydrogen peroxide, respectively. In addition, myeloperoxidase (MPO) activity was assessed by enzyme-linked immunosorbent assay method (ELISA) to estimate neutrophil infiltration and associated inflammation in the gastric tissue.

## Anti-inflammatory activity

Prior to euthanasia, whole blood samples were collected from the rats via cardiac puncture under anesthesia for subsequent analysis of inflammatory cytokines (IL-1 $\beta$ , IL-6, TNF- $\alpha$ ). Serum was separated by centrifugation (3,000 rpm for 15 min at 4°C) and stored at -80°C until assayed. This procedure ensured minimal stress to the animals and alignment with ethical guidelines. The serum levels of IL-1 $\beta$ , IL-6, and TNF- $\alpha$  were measured using ELISA kits, following the manufacturer's instructions. Absorbance was read at 450 nm using a microplate reader (Eppendorf, Germany). To maintain consistency in the assay, each plate included both positive control (FBS) and negative control (PBS) samples.

## Statistical analysis

Statistical analysis was performed using one-way analysis of variance (ANOVA), followed by Tukey's post-hoc test to identify significant differences between groups by Graph pad prism (version8, USA). The results of oxidative stress and inflammatory marker analyses are presented as the mean of triplicate measurements. A p-value of less than 0.05 was considered indicative of statistical significance.

## Findings

Based on the results obtained from the histologic evaluation conducted both macroscopically and via H&E staining, the histopathological indices (Table 1) indicate that, overall, DHA intervention significantly contributes to the improvement of aspirin-induced ulcer inflammation in both low- and high-dose groups.

According to the findings on day 9 of the study (Figure 1A), gastric tissue exhibited signs of inflammation and hemorrhage. H&E staining clearly revealed structural differences between groups at the epithelial, glandular, and inflammatory levels. Historiological results demonstrate that aspirin alone (in untreated control groups) induced gastritis, inflammatory infiltration, and gastric mucosal damage (Figure 1B).

Pathological analysis (Table 1) shows that the outcomes for inflammatory infiltration, epithelial degeneration, gastric gland status, mucosal thickness, and tissue repair potential were relatively similar between the DHA-H and omeprazole-treated groups. Notably, deep ulcers or necrosis were not observed in the DHA-treated groups (Figure 1B).

**Table 1.** Histopathological evaluation of tissue damage

Parameter	Aspirin Group	DHA-L (100 mg/kg)	DHA-H (300 mg/kg)	Omeprazole (20 mg/kg)
Inflammatory Infiltration	3 (Severe)	1 (Mild)	1 (Mild)	1 (Mild)

Epithelial Degeneration	3 (Severe) <sup>a</sup>	1 (Mild)	0.5 (Minimal)	0.5 (Minimal)
Gastric Gland Status	Disrupted	1 (Mild alteration)	0.5 (Near normal)	0.5 (Near normal)
Mucosal Thickness (μm)	220 ± 40 <sup>b</sup>	380 ± 30	420 ± 35	410 ± 30
Tissue Repair Potential	1 (Low)	2 (Moderate)	3 (High)	3 (High)

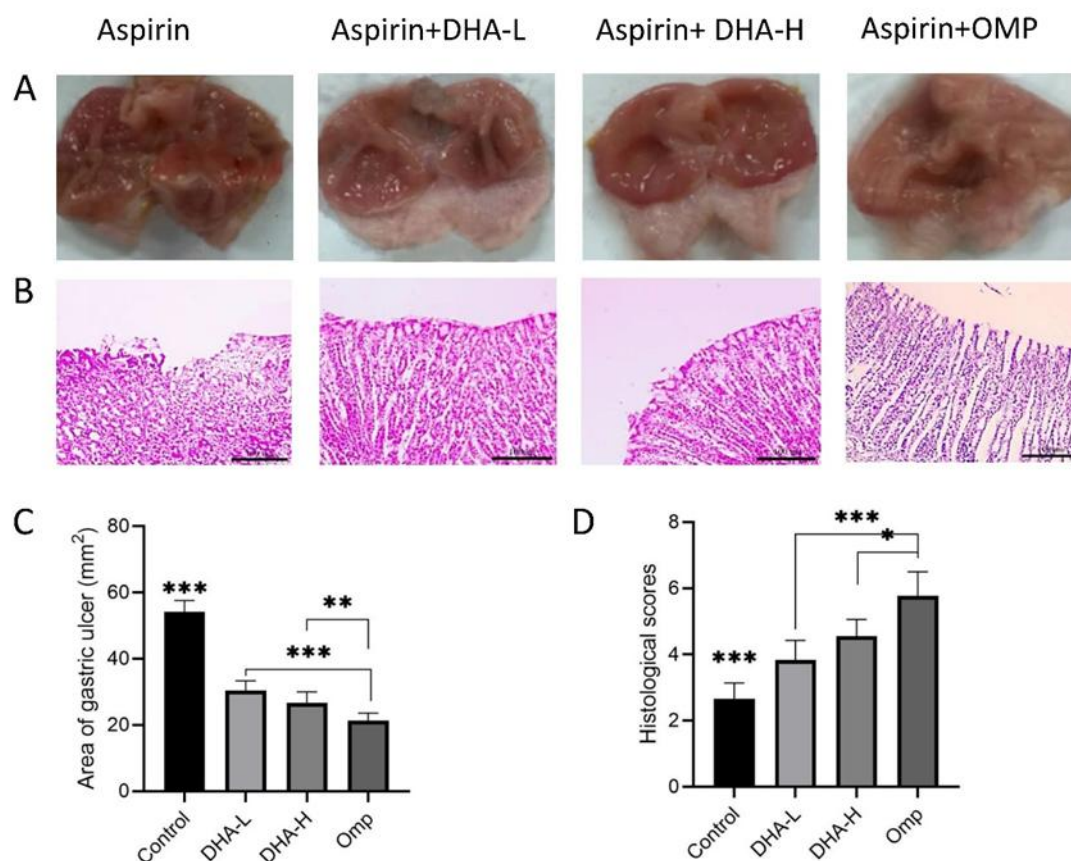
a: 0 = None, 0.5 = Minimal, 1 = Mild, 2 = Moderate, 3 = Severe.    b: Mucosal thickness data presented as mean ± SD.

According to Figure 1C, the ulcerated surface area was significantly reduced ( $p < 0.001$ ) in the treatment groups compared to the control group. Among the treatment groups, the use of omeprazole demonstrated a notably greater reduction in gastric ulcers compared to both the DHA-L and DHA-H groups ( $p = 0.04$  and  $p < 0.001$ , respectively). These findings are consistent with the histopathological analysis, which revealed no significant difference in tissue damage between the two DHA groups, though both were significantly lower than the omeprazole group.

The administration of DHA (particularly at high doses) exhibited substantial protective effects similar to omeprazole, likely mediated through anti-inflammatory and antioxidant mechanisms. Although macroscopic and microscopic results indicated that both low and high concentrations of DHA were significantly less effective than omeprazole, their use still led to a statistically significant improvement in aspirin-induced ulcers compared to the control group.

The data demonstrate a clear dose-dependent effect of DHA on histopathological outcomes. The control group exhibited the lowest mean histopathological score, approximately 2.5, which was significantly different from all other groups ( $p < 0.001$ ). This indicates that the baseline condition serves as a robust reference for assessing the impact of DHA and omeprazole group. In the DHA-L group, the histopathological score increased to approximately 3.5, representing a statistically significant elevation compared to the control group ( $p < 0.05$ ). This suggests that even at a low dose, DHA induces measurable changes in histopathology. Further, the DHA-H group showed a more pronounced increase in histopathological scores, reaching approximately 4.5. This score was significantly higher than the control group ( $p < 0.001$ ), highlighting a dose-dependent exacerbation of histopathological changes with increasing DHA concentrations (Figure 1D).





**Figure 1.** Histopathological analysis of aspirin-induced gastric ulcers in rats treated with DHA and omeprazole.

(A) Macroscopic evaluation of gastric ulcers on day 14 post-induction. The stomach tissues were excised, opened along the greater curvature, and rinsed with saline. Visible lesions are shown in the ulcer control group (Aspirin Group), while reduced ulcer areas are observed in DHA-treated (DHA-L: 100 mg/kg; DHA-H: 300 mg/kg) and omeprazole-treated (Omp: 20 mg/kg) groups. (B) Microscopic assessment via H&E staining (40× magnification; scale bar: 100 μm). Key pathological features are for Aspirin group, severe inflammatory cell infiltration, epithelial degeneration, and disrupted glandular architecture, for DHA-L Group, mild inflammatory infiltration and partial restoration of mucosal integrity, and to DHA-H and Omp, Near-normal mucosal thickness, minimal inflammation, and intact gastric glands. (C) Quantification of ulcer severity expressed as mean ulcer area (mm<sup>2</sup> ± SD). (D) istopathological scoring

(mean ± SD) of tissue damage, including inflammatory infiltration, epithelial degeneration, and mucosal thickness. DHA-L: Low-dose DHA; DHA-H: High-dose DHA; Omp: Omeprazole, \*p < 0.05, \*\* p<0.01, and \*\*\*p < 0.001.

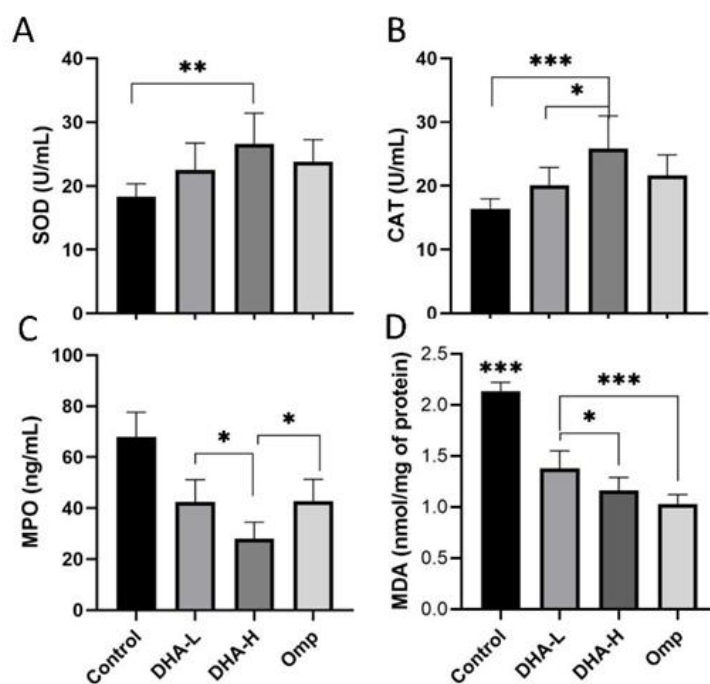
Figure 2A illustrates significant alterations in SOD enzyme activity across treatment groups. In the control group, SOD activity was at the lowest level depicted in the graph, indicating suppression of the primary antioxidant defense system by aspirin under the oxidative stress conditions established in the model baseline. DHA administration compensated for this deficit in a dose-dependent manner. Treatment with DHA-L increased SOD activity, whereas DHA-H induced a statistically significant and marked elevation (p = 0.006). The omeprazole group also exhibited elevated SOD

activity compared to the control, though this increase was less pronounced than that observed with DHA-H. These findings clearly demonstrate the concentration-dependent efficacy of DHA in activating the key defensive enzyme SOD.

A significant alteration in CAT enzyme activity across the treatment groups (Figure 2B) was observed. In the control group, catalase activity was recorded at its lowest level, indicating impairment in the antioxidant defense system and accumulation of reactive oxygen species (ROS) in the baseline model. DHA administration led to a dose-dependent restoration of enzyme activity. Treatment with DHA-L resulted in increased catalase activity compared to the control group, but it was the DHA-H group that exhibited a statistically significant difference relative to both the control and DHA-L groups ( $p < 0.001$  and  $p = 0.04$ , respectively). The omperazole group also showed a notable improvement compared to the control, though this level remained lower than that achieved with DHA-H. This response pattern confirms a strong dose-dependent effect of DHA in modulating catalase enzyme activity.

In the control group, the highest level of MPO was observed, indicating strong inflammatory activity and neutrophil infiltration in the target tissue (Figure 2C). DHA administration led to a dose-dependent significant reduction in this inflammatory marker. Treatment with DHA-L reduced MPO levels to approximately 43 ng/mL, whereas DHA-H resulted in a more pronounced reduction ( $p = 0.03$ ), reaching around 32 ng/mL. The omperazole group also exhibited a reduction comparable to DHA-L, but this effect was significantly weaker than that of DHA-H. This pattern clearly and consistently confirms the dose-dependent efficacy of DHA in suppressing the inflammatory response.

MDA levels were quantified as an index of lipid peroxidation and oxidative stress. The Control group received aspirin only and exhibited a significant elevation in MDA levels compared to treated groups. Animals treated with DHA-L and DHA-H showed a significant reduction in MDA levels, with the high dose being more effective ( $p = 0.03$  vs. DHA-L). Treatment with omperazole resulted in the most pronounced decrease in MDA levels, significantly lower than the Control group ( $p < 0.001$ ).



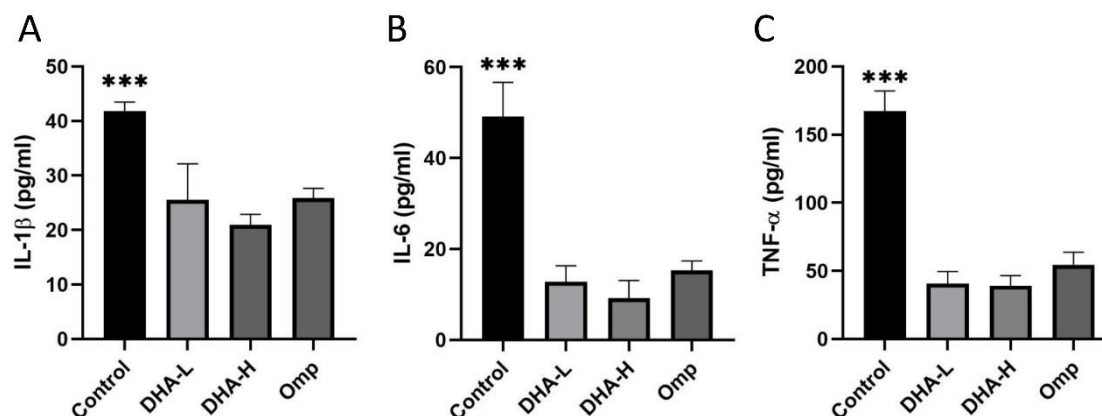
**Figure 2.** Effect of DHA and Omperazole on gastric tissue superoxide dismutase (SOD), catalase (CAT), myeloperoxidase (MPO), and malondialdehyde (MDA) levels in aspirin-induced gastric ulcer in rats. Data are presented as mean  $\pm$  SD (n = 6). Statistical significance: \*p < 0.05, \*\*p < 0.01, and \*\*\*p < 0.001. DHA-L: Low-dose DHA; DHA-H: High-dose DHA; Omp: Omeprazole.

Figure 3A illustrates the changes in the level of the pro-inflammatory cytokine IL-1 $\beta$  across treatment groups. In the control group, the IL-1 $\beta$  level was recorded within the range of 40–50 pg/mL, indicating high activity of inflammatory pathways in the baseline model. DHA administration induced a significant dose-dependent reduction in this cytokine. Treatment with DHA-L decreased IL-1 $\beta$  levels to approximately 20–30 pg/mL, whereas DHA-H led to a more pronounced reduction compared to both DHA-L and omeprazole. Notably, treatment in all intervention groups resulted in a statistically significant decrease in tissue IL-1 $\beta$  levels compared to the control group.

In the control group, the IL-6 level was observed within the range of 40–60 pg/mL, indicating the

activation of inflammatory pathways in the studied model. Administration of DHA reduced the level of this cytokine to below 20 pg/mL. This reduction demonstrates the anti-inflammatory effect of DHA even at low doses.

Figure 3C illustrates the changes in the levels of the inflammatory cytokine TNF- $\alpha$  across different treatment groups. In the control group, TNF- $\alpha$  levels were observed within the range of 20–30 pg/mL, indicating a robust activation of inflammatory pathways in the studied model. This significant increase in TNF- $\alpha$  reflects a systemic inflammatory response and the activation of the cytokine cascade. The results demonstrate that in the treatment groups, tissue TNF- $\alpha$  levels were significantly reduced (p < 0.001) compared to the control group.



**Figure 3.** Effects of different treatments on cytokine levels. (A) IL-1 $\beta$ . (B) IL-6. (C) TNF- $\alpha$ . Data are presented as mean  $\pm$  SD. Statistical significance is p < 0.05). DHA-L: Low-dose DHA; DHA-H: High-dose DHA; Omp: Omeprazole.

## Discussion

In this study, the aim is to investigate the anti-ulcerative properties of DHA in an aspirin-induced model in rats. Antioxidant activities in different groups, as well as histopathological changes, were examined. The accumulated evidence from animal studies demonstrates that omega-3 fatty acids, particularly EPA and DHA from fish oil, effectively

inhibit offensive mucosal factors and oxidative stress while augmenting defensive mucosal factors (11). Studies examining the molecular mechanisms of omega-3 PUFAs in ethanol-induced gastric ulcer models have found significant changes in oxidative stress markers. After omega-3 treatment, researchers observed a significant depletion of gastric tissue NO, lipid peroxidation (L-MDA), and glutathione (GSH)



concentrations, along with marked increases in CAT activity compared to untreated ulcerated rats (12).

Furthermore, quantitative PCR results revealed that omega-3 significantly down-regulated the mRNA gene expression levels of TNF- $\alpha$ , MOP, and inducible nitric oxide synthase (iNOS) in the stomach tissue, confirming its anti-inflammatory mechanism (13).

Histopathological studies clearly demonstrate that the healing process in various treatment groups is better than in the control group, and DHA has effectively accelerated wound healing. Similar studies exist that support these findings (12). Consistent with these previous findings, our study also demonstrated that docosahexaenoic acid (DHA), to a considerable extent and in a manner comparable to omeprazole, was able to heal aspirin-induced gastric ulcers, significantly reduce oxidative stress, improve histopathological parameters, and decrease the expression levels of inflammatory cytokines.

In this study, the superiority of DHA-H over omeprazole further supports the higher potential of this omega-3 fatty acid in the targeted modulation of the oxidative defense network. From a pathophysiological perspective, the increase in SOD activity by DHA has two major consequences. The first consequence is the efficient neutralization of superoxide radicals ( $O_2^-$ ). SOD, as the primary enzymatic defense line, converts superoxide radicals generated under oxidative stress conditions into hydrogen peroxide ( $H_2O_2$ ). The enhancement of enzymatic activity under the influence of DHA-H has significantly improved the capacity to neutralize harmful radicals (14). The second consequence is the regulation of downstream oxidative stress effects. By reducing superoxide levels, the production of secondary ROS such as peroxynitrite ( $ONOO^-$ ) and hydroxyl radicals ( $\bullet OH$ ), which are highly damaging, is limited (15).

The increase in CAT activity under the influence of DHA has a vital consequence. The first is the efficient

elimination of hydrogen peroxide ( $H_2O_2$ ). Catalase specifically decomposes  $H_2O_2$ , produced by SOD or other sources, into harmless water and molecular oxygen. The dose-dependent enhancement of CAT activity by DHA-H notably prevents significant accumulation of  $H_2O_2$ , thereby inhibiting the formation of hydroxyl radicals ( $\bullet OH$ )—the most dangerous ROS, via the Fenton reaction (16).

The decrease in MPO levels under the influence of DHA reflects two key mechanisms. The first mechanism involves MPO as a specific enzyme within the azurophilic granules of neutrophils, and its reduction indicates the inhibition of leukocyte infiltration into inflammatory sites (17). DHA limits neutrophil migration by modulating the expression of adhesion molecules (e.g., ICAM-1) and suppressing chemokine signaling, such as IL-8 (18, 19). The second mechanism entails a reduction in ROS production. MPO acts as a secondary source of ROS by generating hypochlorous acid ( $HOCl$ ) from  $H_2O_2$  and chloride. The dose-dependent decrease in MPO induced by DHA not only suppresses inflammation but also attenuates neutrophil-dependent oxidative stress (20). This mechanism aligns with previous findings (e.g., reduced MDA levels and increased SOD/CAT activity), demonstrating that DHA targets both the inflammatory response and may alter the associated oxidative cascade through the integrated suppression of NF- $\kappa B$  and MAPK pathways (21, 22). Accordingly, the superior efficacy of DHA-H compared to omeprazole further underscores the higher potential of omega-3 fatty acids in systemic inflammation modulation.

The significance of IL-1 $\beta$  reduction and the mechanisms associated with DHA in suppressing inflammasome activation and the IL-1 $\beta$  inflammatory cascade (23).

IL-1 $\beta$  is one of the most potent pro-inflammatory cytokines, produced through the activation of the NLRP3 inflammasome and NF- $\kappa B$  pathways (24). Its marked reduction by DHA-H suggests direct inhibition of the inflammasome and its associated

signaling pathways (25). This effect leads to the suppression of other inflammatory cytokines (such as IL-6 and TNF- $\alpha$ ) and reduced leukocyte infiltration into damaged tissues (26).

The link to oxidative stress and findings from previous studies indicate that IL-1 $\beta$  can enhance the production of ROS, while oxidative stress, in turn, stimulates IL-1 $\beta$  production (27). The concurrent reduction in IL-1 $\beta$ , MPO, and MDA, along with increased activity of antioxidant enzymes SOD and CAT, demonstrates DHA's integrated role in disrupting the vicious cycle of inflammation and oxidative stress (28). These mechanisms are likely mediated through the inhibition of TLR4/NF- $\kappa$ B/NLRP3 pathways and the activation of Nrf2/ARE signaling (29).

The reduction of IL-6 is a key indicator of anti-inflammatory activity, reflecting inhibition of NF- $\kappa$ B and JAK/STAT pathways (reference). Clinically, decreased IL-6 limits pro-inflammatory signaling, leukocyte infiltration, and tissue damage. This aligns with reduced MPO and IL-1 $\beta$  levels, suggesting that DHA exerts protective effects by modulating pro-inflammatory cytokine networks. Notably, IL-6 suppression is critical in preventing chronic inflammation and its complications (30).

The results of this study comprehensively demonstrate that DHA prevents aspirin-induced gastric ulcers. These effects were dose-dependent, with the DHA-H exhibiting effects comparable to or even superior to omeprazole across several parameters. From a clinical perspective, these findings highlight the potential of DHA as a complementary or alternative therapeutic agent for NSAID-induced gastropathy, particularly in patients who are unresponsive to or intolerant of proton pump inhibitors (PPIs). Moreover, co-administration of DHA with PPIs may exert synergistic effects and reduce the required dosage of PPIs (10).

By elucidating the dual and complementary roles of DHA in simultaneously attenuating oxidative stress

(via upregulation of SOD and CAT enzymes) and suppressing inflammation (through downregulation of inflammatory cytokines such as TNF- $\alpha$ , IL-1 $\beta$ , and IL-6) in an aspirin-induced gastric ulcer model, this study takes a novel step toward understanding the therapeutic potential of omega-3 fatty acids. While this study demonstrates the efficacy of DHA in mitigating aspirin-induced gastric ulcers through antioxidant and anti-inflammatory actions, the precise molecular pathways, including, NF- $\kappa$ B, COX, or NLRP3 inflammasome remain to be directly investigated. For instance, the ulcerogenic effects of DHA are partly mediated via COX-1 inhibition and NF- $\kappa$ B activation, while the anti-inflammatory properties of DHA may involve suppression of these pathways, as suggested by prior studies (10, 25).

However, several limitations remain, including the lack of investigation into the involved signaling pathways, exclusion of other omega-3 family members (such as eicosapentaenoic acid, EPA), absence of long-term and sequential dosing assessments of DHA, and the need for pharmacokinetic studies to determine optimal clinical dosing.

Future directions should include more in-depth mechanistic studies to identify specific molecular targets of DHA, evaluation of synergistic combinations with current drugs (e.g., PPIs), and development of novel formulations, such as targeted nanoparticle-based delivery systems, to enhance the gastric bioavailability and efficacy of DHA. Additionally, forthcoming clinical trials should focus on high-risk populations for NSAID-induced gastropathy to assess the translational potential of these findings into clinical practice.

## Conclusion

DHA exhibited significant anti-ulcerative effects in an aspirin-induced gastric ulcer model by reducing oxidative stress, modulating inflammatory cytokines, and enhancing mucosal healing. The high-dose DHA group showed comparable or superior efficacy to omeprazole. These findings support potential of

DHA as a complementary or alternative treatment for NSAID-induced gastropathy and warrant further investigation into its mechanisms, optimal dosing, and clinical applicability.

### Acknowledgements

We sincerely thank all the medical staff who participated in this study.

### Ethics approval

All animal experiments were performed according to accordance with the U.K. Animals (Scientific Procedures) Act, and protocol approved by the Ethics Committee of Ilam Medical University (approval number: R.MEDILAM. REC.1400.133).

### Financial support

No financial support was provided for conducting this study.

### Conflict of interest

The authors declare that there is no conflict of interest.

### Authors' contributions

All authors contributed significantly to the conception, design, data collection, analysis, and writing of the manuscript. All authors reviewed and approved the final version of the article.

### Abbreviation

ALT: Alanine transaminase; CAT: Catalase; DHA: Docosahexaenoic acid; DHA-H: High-dose DHA; DHA-L: Low-dose DHA; DM: Diabetes mellitus; ELISA: Enzyme-linked immunosorbent assay; EPA: Eicosapentaenoic acid; FBS: Fetal bovine serum; GSH: Glutathione; H&E: Hematoxylin and eosin; HOCl: Hypochlorous acid; ICAM-1: Intercellular adhesion molecule 1; IL-1 $\beta$ : Interleukin-1 beta; IL-6: Interleukin-6; iNOS: Inducible nitric oxide synthase; MDA: Malondialdehyde; MPO: Myeloperoxidase; NF- $\kappa$ B: Nuclear factor kappa-light-chain-enhancer of activated B cells; NLRP: NLR Family Pyrin Domain Containing; NO: Nitric oxide; NSAIDs: Nonsteroidal anti-inflammatory drugs; Omp: Omeprazole;

ONOO<sup>-</sup>: Peroxynitrite; PBS: Phosphate-buffered saline; PGE2: Prostaglandin E2; PPIs: Proton pump inhibitors; PUFAs: Polyunsaturated fatty acids; ROS: Reactive oxygen species; SOD: Superoxide dismutase; TBARS: Thiobarbituric acid reactive substances; TNF- $\alpha$ : Tumor necrosis factor-alpha; •OH: Hydroxyl radicals.

## References

1. Saeed MG, Al-Hamdany EK, Ismail HK. Pathological and histomorphometric study of comparative gastric ulcer induced by indomethacin, aspirin, and ethanol in rats. 2023.
2. Al-garni AA, Khalifa FK, Zeyadi MA. Comparative study of the efficacy of prebiotics and probiotics as dietary supplements in rats with gastric ulcer. *J Pharm Res Int*. 2021;33:137-45.
3. Qui B-S, Mei Q-B, Liu L, Tchou-Wong K-M. Effects of nitric oxide on gastric ulceration induced by nicotine and cold-restraint stress. *World Journal of Gastroenterology*. 2004;10(4):594.
4. Motawee ME, Hassan F, Mohie PM, Khalifa MM, Elbastawisy YM. Possible protective effect of each of Omega-3 PUFA and leptin on indomethacin-induced gastric ulcer in rats with type II DM. *Bulletin of Egyptian Society for Physiological Sciences*. 2022;42(4):329-43.
5. Khoshnood S, Negahdari B, Kaviar VH, Sadeghifard N, Abdullah MA, El-Shazly M, et al. Amoxicillin-docosahexaenoic acid encapsulated chitosan-alginate nanoparticles as a delivery system with enhanced biocidal activities against *Helicobacter pylori* and improved ulcer healing. *Frontiers in microbiology*. 2023;14:1083330.
6. Salinas-Nolasco C, Pérez-Hernández E, Garza S, Park HG, Brenna JT, Castañeda-Hernández G, et al. Antioxidative action of alpha-linolenic acid during its gastroprotective effect in an indomethacin-induced gastric injury model. *Preventive Nutrition and Food Science*. 2025;30(2):132.
7. Sakr HI, Khalifa MM, Saleh MAS, Rashed LA, Khowailed AA. The effect of omega-3 therapy on induced hyperacidity. *J Med Sci Clin Res*. 2016;4(2):9222-34.
8. Coppey L, Davidson E, Shevalye H, Obrosof A, Torres M, Yorek MA. Progressive loss of corneal nerve fibers and sensitivity in rats modeling obesity and type 2 diabetes is reversible with omega-3 fatty acid intervention: supporting cornea analyses as a marker for peripheral neuropathy and treatment. *Diabetes, Metabolic Syndrome and Obesity*. 2020;1367-84.
9. He J, Pham TL, Kakazu A, Bazan HE. Recovery of corneal sensitivity and increase in nerve density and wound healing in diabetic mice after PEDF plus DHA treatment. *Diabetes*. 2017;66(9):2511-20.
10. Pineda-Peña EA, Jiménez-Andrade JM, Castaneda-Hernandez G, Chávez-Piña AE. Docosahexaenoic acid, an omega-3 polyunsaturated acid protects against indomethacin-induced gastric injury. *European Journal of Pharmacology*. 2012;697(1-3):139-43.
11. Khare S, Asad M, Dhamanigi SS, Prasad VS. Antiulcer activity of cod liver oil in rats. *Indian Journal of Pharmacology*. 2008;40(5):209-14.
12. El Senosi Y, Mahfouz M, Hussein A. Omega-3 polyunsaturated fatty acids as therapeutic options for the treatment of ethanol induced gastric ulcer in rats. *Benha Veterinary Medical Journal*. 2018;34(1):48-65.
13. Chon J-E, Lai KZH, Semnani-Azad Z, Metherel AH, Jenkins DJ, Bazinet RP, et al. Omega-3 Polyunsaturated Fatty Acids and Adipose Tissue Inflammation in Humans: A Scoping Review. *Nutrition Reviews*. 2025:nuaf089.
14. Süleyman O, Mahinur K, Musa A, İsmail Z. The effects of omega-3 fatty acids on antioxidant enzyme activities and nitric oxide levels in the cerebral cortex of rats treated ethanol. *Biomeditsinskaya khimiya*. 2024;70(2):83-8.
15. Lyudinina AY, Parshukova OI, Bojko ER. n-3 Polyunsaturated fatty acids are associated with stable nitric oxide metabolites in highly trained athletes. *Cells*. 2024;13(13):1110.
16. Ogłuszka M, Lipiński P, Starzyński RR. Interaction between iron and omega-3 fatty acids metabolisms: where is the cross-link? *Critical Reviews in Food Science and Nutrition*. 2022;62(11):3002-22.
17. Capó X, Martorell M, Sureda A, Tur JA, Pons A. Effects of docosahexaenoic supplementation and in vitro vitamin C on the oxidative and inflammatory neutrophil response to activation. *Oxidative Medicine and Cellular Longevity*. 2015;2015(1):187849.
18. Rodrigues HG, Sato FT, Curi R, Vinolo MA. Fatty acids as modulators of neutrophil recruitment, function and survival. *European journal of pharmacology*. 2016;785:50-8.
19. Jensen KN, Omarsdottir SY, Reinhardsdottir MS, Hardardottir I, Freysdottir J. Docosahexaenoic acid modulates NK cell effects on neutrophils and their crosstalk. *Frontiers in Immunology*. 2020;11:570380.
20. Zhang Y, Liu L, Sun D, He Y, Jiang Y, Cheng K-W, et al. DHA protects against monosodium urate-induced inflammation through modulation of oxidative stress. *Food & function*. 2019;10(7):4010-21.
21. Mirghaed MT, Ghasemian SO, Nasab SFM, Rahimi K. Effects of fish oil on ethanol-induced gastric ulcer in rats: inflammatory responses and oxidative stress. *Annals of Medicine and Surgery*. 2024;86(2):819-25.
22. du Toit-Kohn J-L, Louw L, Engelbrecht A-M. Docosahexaenoic acid induces apoptosis in colorectal carcinoma cells by modulating the PI3 kinase and p38 MAPK pathways. *The Journal of nutritional biochemistry*. 2009;20(2):106-14.
23. Netea MG, van de Veerdonk FL, van der Meer JW, Dinarello CA, Joosten LA. Inflammasome-independent regulation of IL-1-family cytokines. *Annual review of immunology*. 2015;33(1):49-77.

24. Grebe A, Hoss F, Latz E. NLRP3 Inflammasome and the IL-1 Pathway in Atherosclerosis. *Circulation research*. 2018;122(12):1722-40.
25. Martínez-Micaelo N, González-Abuín N, Pinent M, Ardévol A, Blay M. Dietary fatty acid composition is sensed by the NLRP3 inflammasome: omega-3 fatty acid (DHA) prevents NLRP3 activation in human macrophages. *Food & function*. 2016;7(8):3480-7.
26. Libby P. Targeting inflammatory pathways in cardiovascular disease: the inflammasome, interleukin-1, interleukin-6 and beyond. *Cells*. 2021;10(4):951.
27. Dinarello CA. IL-1: Discoveries, controversies and future directions. *European journal of immunology*. 2010;40(3):599-606.
28. Brigelius-Flohé R, Banning A, Kny M, Böhl G-F. Redox events in interleukin-1 signaling. *Archives of biochemistry and biophysics*. 2004;423(1):66-73.
29. Zhang X, Du Q, Yang Y, Wang J, Dou S, Liu C, et al. The protective effect of Luteolin on myocardial ischemia/reperfusion (I/R) injury through TLR4/NF- $\kappa$ B/NLRP3 inflammasome pathway. *Biomedicine & Pharmacotherapy*. 2017;91:1042-52.
30. Lv X, Ding S. Unraveling the Role of STAT3 in Cancer Cachexia: Pathogenic Mechanisms and Therapeutic Opportunities. *Frontiers in Endocrinology*. 2025;16:1608612.